

Fascia Iliaca Compartment Block: LANDMARK AND ULTRASOUND APPROACH

ANAESTHESIA TUTORIAL OF THE WEEK 193

23rd AUGUST 2010

Dr Christine Range, Specialist Registrar Anaesthesia

Dr Christian Egeler, Consultant Anaesthetist

Morrison Hospital, Swansea

Correspondence - C Range: range.christine@yahoo.co.uk



QUESTIONS

1. Please answer true or false: Anatomy relevant to the Fascia Iliaca Compartment Block:
 - a. The lateral femoral cutaneous nerve originates from the spinal roots L2, L3 and L4.
 - b. The femoral nerve gives motor supply to the knee flexors.
 - c. Most of the lower leg receives sensory supply from the sciatic nerve.
 - d. Behind the inguinal ligament, the femoral nerve, artery and vein all lie within one sheath.
 - e. The fascia iliaca covers three of the four main nerves of the lower extremity.

2. Please answer true or false: The following are indications for the Fascia Iliaca Compartment Block:
 - a. Analgesia for ankle surgery
 - b. Pre- and post-operative analgesia for patients with fractured neck of femur.
 - c. As sole anaesthetic for above knee amputation.
 - d. In anticoagulated patients, in whom neuraxial blockade is contra-indicated.
 - e. The intention to paralyse the hip adductor muscles, e.g. for TURBT.

3. Please answer true or false: With regards to techniques of Fascia Iliaca Compartment Block:
 - a. The landmark technique is considered to be safer than a direct femoral nerve block, because it keeps a greater distance to the femoral nerve and vessels.
 - b. The bony landmarks used are the anterior superior iliac spine and the pubic symphysis.
 - c. As the injection is away from nerves and vessels, sharp needles are ideal for this block.
 - d. For the ultrasound technique, a high frequency ultrasound probe (13-6 MHz) is ideal.
 - e. With the ultrasound technique, the local anaesthetic spread should be observed.

INTRODUCTION

The fascia iliaca compartment block (FICB) was initially described by Dalens et al. on children using a landmark technique. It is a low-skill, inexpensive method to provide peri-operative analgesia in patients with painful conditions affecting the thigh, the hip joint and/or the femur. Use of ultrasound to aid identification of the fascial planes may lead to faster onset, denser nerve blockade and an increased rate of successful blocks.

This article will cover the relevant anatomy of the fascia iliaca compartment, give the possible applications of the FICB and describe approaches to perform it using landmarks or ultrasound, followed by a brief section on trouble shooting.

ANATOMY

The nervous supply to the lower extremity is provided through four major nerves: the sciatic nerve, the femoral nerve, the obturator nerve and the lateral femoral cutaneous nerve. The femoral nerve, the lateral femoral cutaneous nerve and the obturator nerve all arise from the lumbar plexus (Fig 1). The sciatic nerve originates from the lumbar, as well as the sacral plexus (lumbosacral plexus).

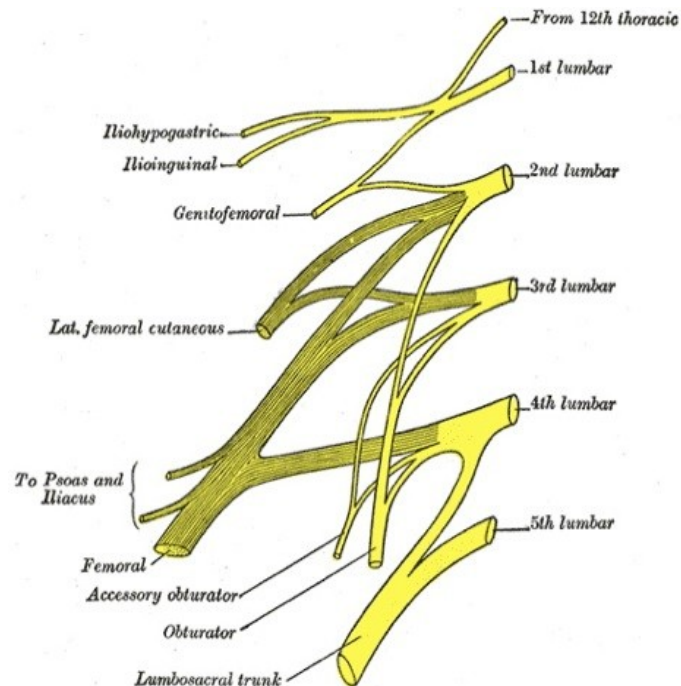


Figure 1. Right lumbar plexus. Note the lumbosacral trunk arising from 4th and 5th lumbar root to join the sacral plexus and form part of the sciatic nerve

The femoral nerve

This is the largest branch of the lumbar plexus, originating from the posterior divisions of the anterior rami of the lumbar nerves 2, 3 and 4 (Fig 1). It descends through the posterior third of the psoas major muscle and emerges from its lateral border and continues caudally between the bulk of the psoas major and the iliacus muscle. It enters the thigh behind the inguinal ligament, lying lateral to the femoral artery and on top of the iliacus muscle. It is separated from the artery by the fascia iliaca. It gives motor supply to the knee extensors (quadriceps femoris and sartorius muscles) and sensory supply to the anteromedial surface of the thigh and the medial aspect of the lower leg, ankle and foot via its terminal branch, the saphenous nerve.

The obturator nerve

This nerve originates from the anterior divisions of the anterior rami of the lumbar nerves 2, 3 and 4 (Fig 1). Descending within the psoas major muscle, it emerges at the medial border and runs behind the

common iliac vessels and lateral to the internal iliac vessels. It enters the thigh through the obturator foramen and splits into anterior and posterior branches, which lie between adductor longus and brevis and adductor brevis and magnus, respectively (Fig 2). Its motor fibres supply the hip adductors. Sensory supply is variable and often only to a small area on the medial aspect of the thigh but can reach as far as just proximal to the knee. The psoas muscle and pectineus muscle separate the obturator nerve from the femoral nerve along its course and therefore this nerve is not reliably blocked by a fascia iliaca compartment injection.

The lateral femoral cutaneous nerve (LFCN)

The LFCN arises from L2 and L3 (Fig 1). It emerges from the lateral border of the psoas major muscle and runs on the ventral surface of the iliacus muscle, heading towards the anterior superior iliac spine (ASIS). It is covered on its course by the fascia iliaca. Passing behind the inguinal ligament close to its lateral insertion at the ASIS, the LFCN perforates the fascia iliaca. Once in the thigh it splits into its terminal cutaneous branches, which usually cross over the sartorius muscle and are covered by the fascia lata. As the name suggests it gives sensory supply to the lateral aspect of the thigh as far distal as the knee.

The sciatic nerve

The sciatic nerve is formed of fibres from both, the anterior and posterior divisions of the anterior roots of L4 to S3 via the lumbosacral plexus. It supplies all the muscles in the posterior compartment of the thigh and all the muscles below the knee. The sensory supply pattern of the sciatic nerve reflects the motor supply with the exception of the medial aspect of the lower leg, which is supplied by the saphenous nerve. The sciatic nerve is **not** blocked by a fascia iliaca compartment injection.

The fascia iliaca

Location

- Spans from the lower thoracic vertebrae to the anterior thigh
- Lines the posterior abdomen and pelvis, covering psoas major and iliacus muscle
- Forms the posterior wall of femoral sheath, containing the femoral vessels
- In the femoral triangle covered by fascia lata, blending with it further distally

Attachments

- lateral: thoracolumbar fascia, iliac crest, anterior superior iliac spine, sartorius fascia
- medial: vertebral column, pelvic brim, pectineal fascia
- anterior: posterior part of inguinal ligament, fascia lata

Neurovascular relations

Above the inguinal ligament the femoral vessels lie superficial to the fascia iliaca while the femoral, obturator and LFCN are covered by it in their respective locations. The area behind the inguinal ligament can be divided in a medial and a lateral part:

- Medially, the fascia iliaca forms the posterior wall of the femoral sheath (lacuna vasorum), which contains the femoral artery and vein and the femoral branch of the genitofemoral nerve.
- Laterally, it forms the roof of the lacuna musculorum, which contains the psoas major and iliacus muscles and the femoral nerve. The fascia iliaca separates the lacuna musculorum from the lacuna vasorum with fibres that link to the capsule of the hip joint, thereby forming a functional septum between the two lacunae.

Fascia iliaca compartment

The Fascia Iliaca Compartment is a potential space with the following limits:

- Anteriorly: the posterior surface of the fascia iliaca, which covers the iliacus muscle and, with a medial reflection, every surface of the psoas major muscle
- Posteriorly: the anterior surface of the iliacus muscle and the psoas major muscle.
- Medially: the vertebral column and cranially laterally the inner lip of the iliac crest.
- Cranio medially: it is continuous with the space between the quadratus lumborum muscle and its fascia.

This compartment allows deposition of local anaesthetic of sufficient volumes to spread to at least two of the three major nerves that supply the medial, anterior and lateral thigh with one single injection, namely the femoral nerve and the LFCN (Fig 2). From Dalen's study the fascia iliaca block more reliably blocked the obturator nerve as well as the femoral and lateral femoral cutaneous nerves when compared to the 3-in-1 block.

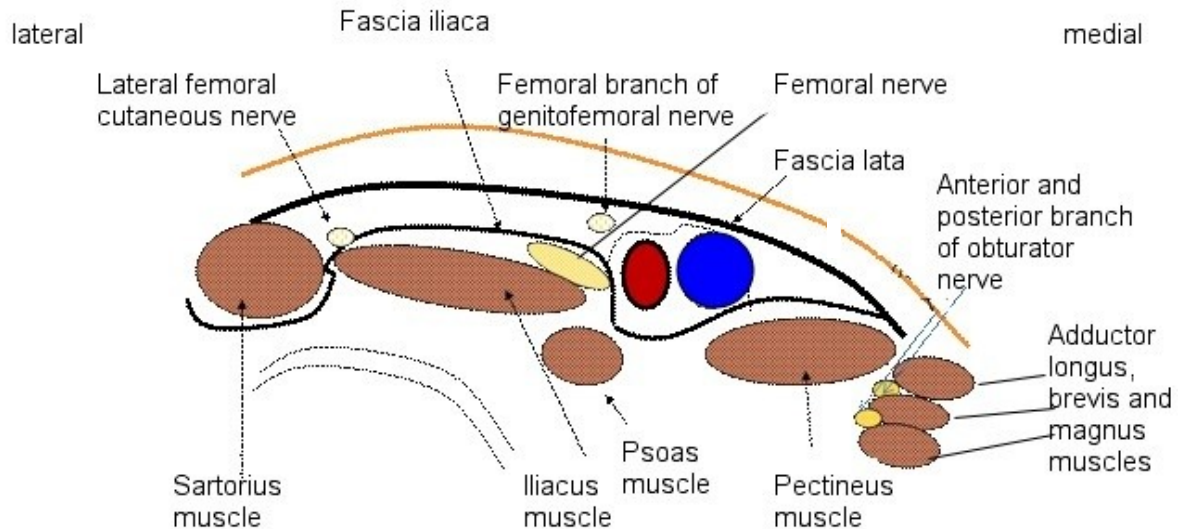


Figure 2. Cross section of the right thigh, just below the anterior superior iliac spine

Key points:

- Innervation of medial, anterior and lateral aspects of thigh comes from L2 to 4
- Fascia iliaca compartment contains three of four major nerves to the leg
- Local anaesthetic injected here reliably reaches the femoral and LFCN only

INDICATIONS

The aim is to reduce the requirements for opioid analgesics with their common side effects. This is especially useful in elderly patients or patients with co-existing respiratory disease. A single shot block is generally used but it is relatively easy to insert a catheter here for a continuous infusion or additional boluses of local anaesthetic.

- Perioperative analgesia for patients with fractured neck or shaft of the femur
- Adjuvant analgesia for hip surgery depending on the surgical approach
- Analgesia for above knee amputation
- Analgesia for plaster applications in children with femoral fracture
- Analgesia for knee surgery (in combination with sciatic nerve block)
- Analgesia for lower leg tourniquet pain during awake surgery

CONTRAINDICATIONS

COMMON TO ALL BLOCKS

- Patient refusal
- Anticoagulation
- Previous femoral bypass surgery
- Inflammation or infection over injection site
- Allergy to local anaesthetics

FICB

- Previous femoral bypass surgery

GENERAL PREPARATION

Confirm the indication, rule out contraindications, obtain informed consent and ensure that you have the required assistance, monitoring and equipment. For details of general preparation see ATOTW tutorial no. 134 “Peripheral nerve blocks – Getting started”.

Specific equipment required

- A blunted or short-bevelled needle, e.g. Tuohy or specialized nerve block needle
- Skin antiseptic solution
- 1-2 ml of 1% Lidocaine for skin infiltration in the awake patient
- 30-40 ml of long-acting local anaesthetic, e.g. 0.25-0.375% Bupivacaine, Levobupivacaine or 0.2-0.5% Ropivacaine. Check you remain within the safe dose appropriate for the patient’s weight and, if necessary, change to a lower concentration of local anaesthetic rather than reducing the volume.

LANDMARK PROCEDURE

The landmarks for this block are the anterior superior iliac spine (ASIS) and the pubic tubercle of the same side. Place one middle finger on the ASIS and the other middle finger on the pubic tubercle. Draw a line between these two points. Divide this line into thirds (the index finger of both hands can be used, Fig 3a). Mark the point 1cm caudal from the junction of the lateral and middle third. This is the injection entry point (Fig 3b and c).

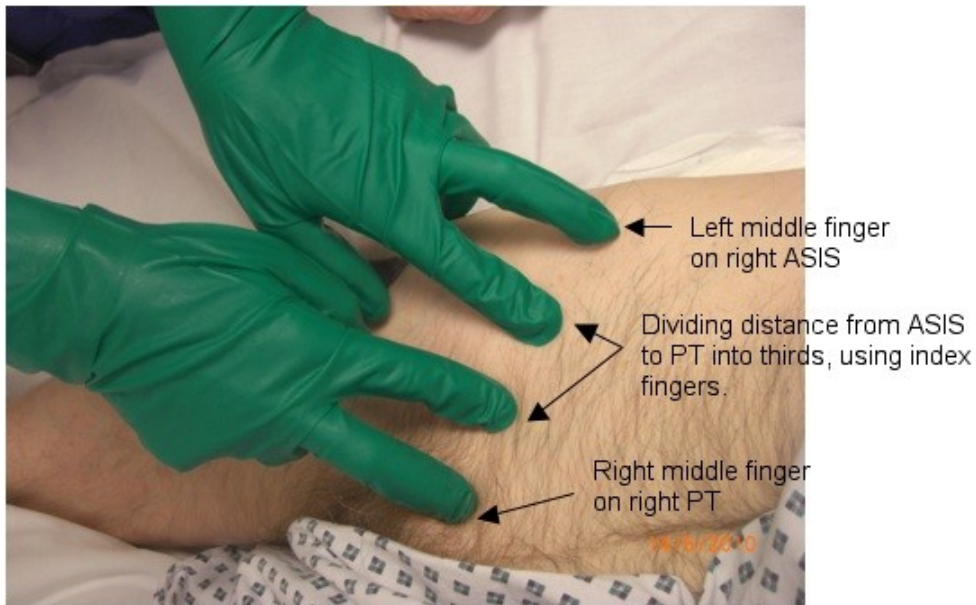


Figure 3a. The injection site for a right-sided FICB. Divide a line between the ASIS and pubic tubercle (PT) into thirds. The left index finger marks the junction of the lateral and middle third of the line joining ASIS with PT.

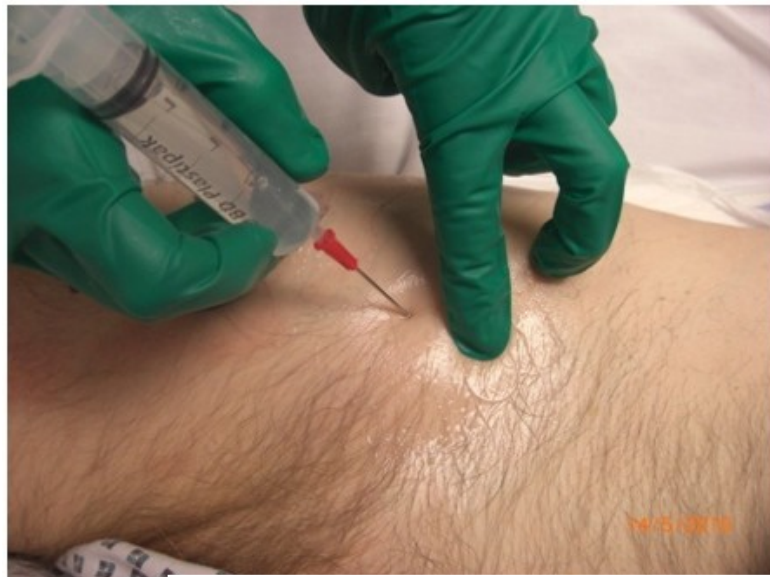

Figure 3b. Right-sided FICB. Injection entry point is approximately 1 cm caudad from the junction of lateral and middle third, indicated by left index finger.

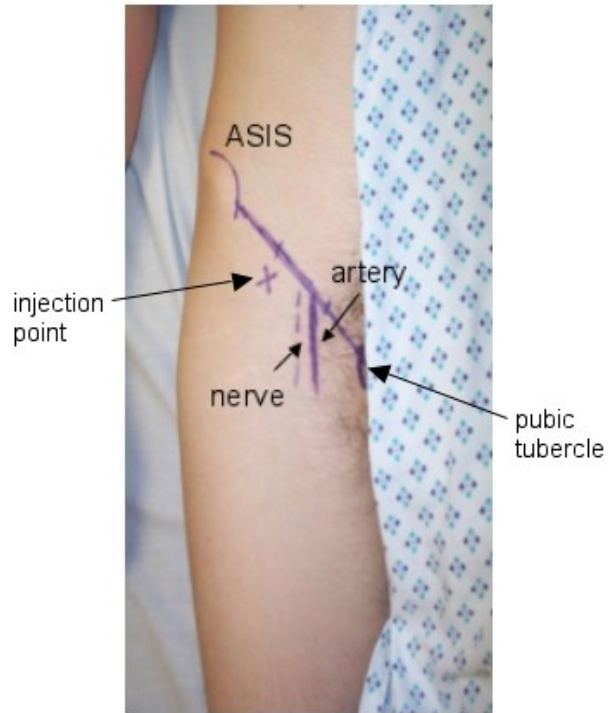


Figure 3c. Landmarks projected onto the skin: Right anterior superior iliac spine (ASIS) and pubic tubercle, with the inguinal ligament as the linking line. The femoral arterial pulse is palpable near the point where the medial and middle third of inguinal ligament meet; the femoral artery is drawn as a solid line. Estimated position of the femoral nerve =dotted line lateral to artery. The injection point is just caudad to the point where the middle and lateral third of the inguinal ligament meet (marked X).

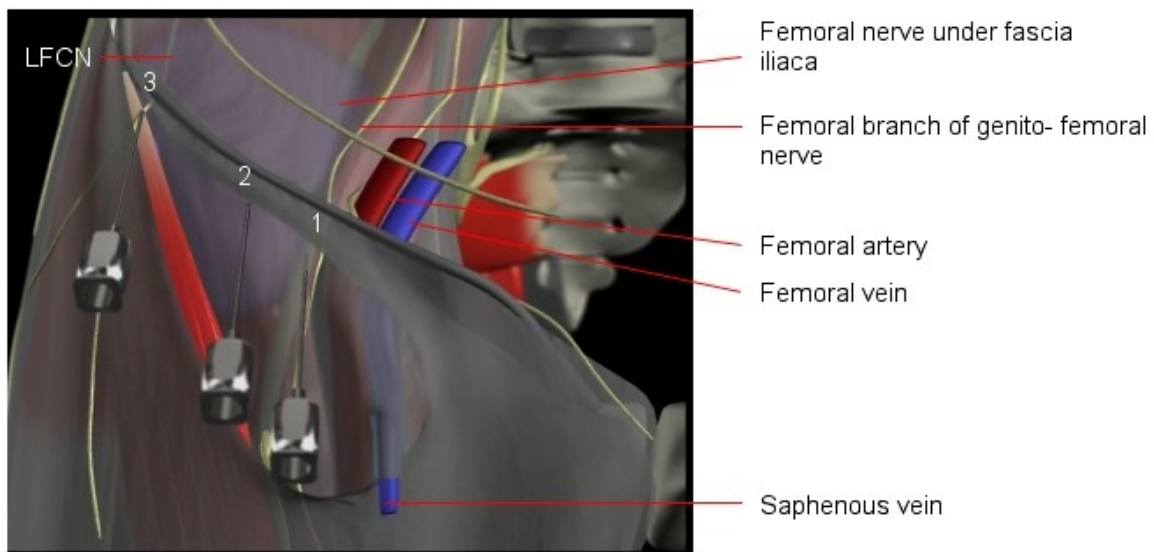


Figure 4. Computer-generated view of the needle insertion sites for a right-sided (1) Femoral nerve block, (2) Fascia iliaca compartment block and (3) Lateral femoral cutaneous nerve block. The fascia lata has been partially removed to reveal the Sartorius muscle and the fascia iliaca.

The image from a computer-generated model in Fig 4 shows that the needle insertion point (2) lies approximately halfway between the femoral and LFCN allowing local anaesthetic to spread and block these two nerves. Due to muscle bulks separating the obturator nerve from the other two nerves, blockade of the obturator nerve with a single injection during a FICB is at best unreliable, despite its location within the same anatomical compartment.

Performing a FICB

- Prepare syringe containing LA, attach to the blunt/short-bevelled needle and flush the needle.
- Identify the landmarks.
- Palpate the ipsilateral femoral pulse at the level of your planned injection site. The pulse should be palpable 1.5 to 2 cm medial to the intended injection point to ensure a safe distance from the femoral nerve to avoid femoral nerve impalement.
- Prepare the skin and infiltrate skin and deeper tissues with 1% Lidocaine in the awake patient.
- Using a blunted or short-bevelled needle pierce the skin at a right angle to its surface.
- Once through the skin adjust the needle angle to about 60 degrees directing the tip cranially.
- Keep the needle in the sagittal plane to avoid the major vessels (medially) and peritoneal cavity (cranially).
- Advance the needle through two distinct “pops” as it perforates first the fascia lata, then the fascia iliaca (the latter of which gives a more subtle “pop”).
- Reduce the angle between needle and skin surface to about 30 degrees and advance the needle further 1-2 mm.
- Aspirate before injection and after every 5 ml injected.
- If aspiration is negative, start injecting the local anaesthetic. There should be no resistance to injection. If there is, the needle tip is likely to be within iliacus muscle. In this case withdraw slightly until injection is easy. There should be no pain or paraesthesia on injection.
- Inject, approximately 20mls slowly, aspirating every 5mls,, then change the syringe and inject the remaining volume. It is common to observe some of the injected fluid coming back through the needle during syringe change (Fig 5).
- If a block needle with an injection port is used, you may not see LA returning.

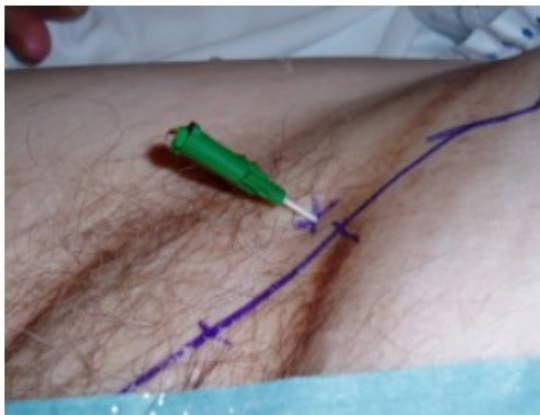


Figure 5. Cannula (Contiplex, BBraun, Melsungen, Germany) in position for right FICB, a drop of local anaesthetic is emerging following disconnection of syringe.

Key points:

- Draw a line between ASIS and pubic tubercle, divide into thirds
- Needle insertion is 1cm caudad to junction between lateral and middle third
- With blunt needle feel two pops
- After negative aspiration, inject local anaesthetic slowly aspirating every 5mls

Catheters

By advancing the needle in a cephalad direction, it is also possible and relatively easy to leave a catheter in place – this can be either a plastic cannula (commercial regional anaesthesia products with cannulae around short-bevelled needles are available), or a catheter through a Tuohy needle. The disadvantage of the catheter as opposed to the cannula is the limited control during insertion over its course within the fascial compartment, which may reduce its efficacy. In our institution we prefer the Contiplex cannula (BBraun, Melsungen, Germany), as its tip will be positioned just in the same place as the needle tip, i.e. between the two nerves.

ULTRASOUND GUIDED APPROACH

With ultrasound (US) the aim is to visually identify the femoral nerve and fascia iliaca and place the local anaesthetic beneath the fascia, lateral to the femoral nerve. Using ultrasound, the fascia iliaca compartment can be approached below as well as above the inguinal ligament. In this article we are going to only discuss the former, the latter being a more recent description and requiring more advanced skills.

For the approach below the inguinal ligament place a high frequency ultrasound probe (13-16 MHz, linear array) in a transverse direction over the anterior thigh below the inguinal ligament (Fig 6).

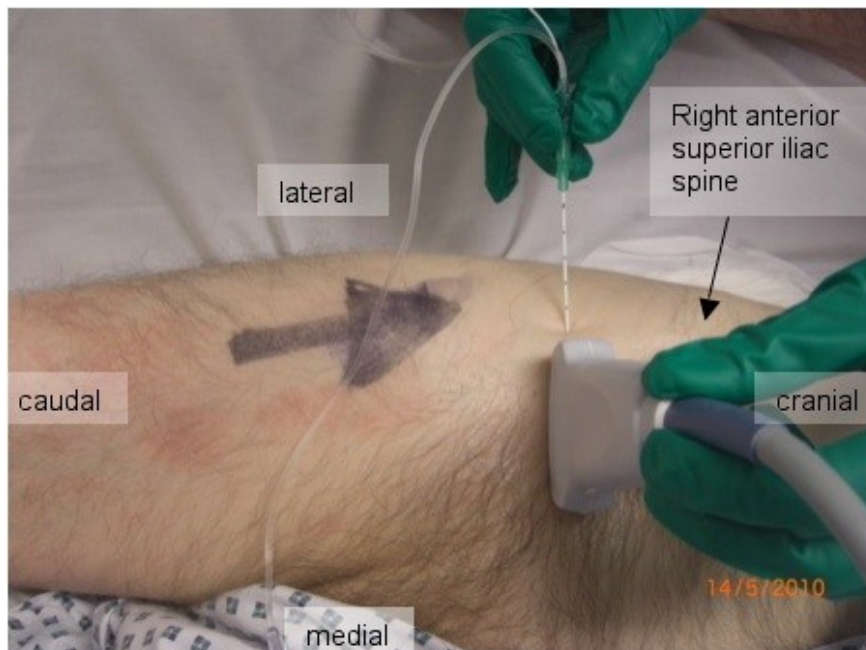


Figure 6. Ultrasound probe and needle placement for in-plane approach to right fascia iliaca compartment distal to the inguinal ligament.

Identify the femoral artery and the iliacus muscle lateral to it, covered by the fascia iliaca. If the division of the femoral artery is visualised, move the probe more cranially. The needle can be inserted in plane (Fig 6, Fig 7) or out of plane (technically more difficult) of the ultrasound beam. Advance the needle until the tip is placed underneath the fascia iliaca (appreciating the give as the fascia is perforated) and confirm negative aspiration, then inject the local anaesthetic. Remember, it should always be easy to inject and the LA should be seen on US. Scanning further cranially after injection of the local anaesthetic shows the cranial spread of the injectate within the fascia iliaca compartment (Fig 8).

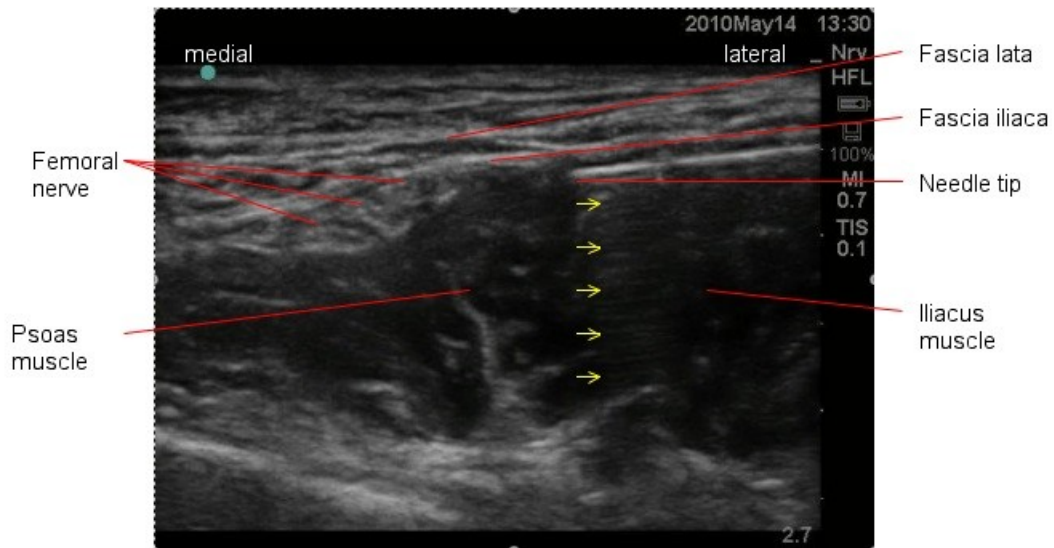


Figure 7. Ultrasound picture of the needle-in-plane approach to a left-sided FICB, below the inguinal ligament. Reverberation artefact from the needle is seen as faint multiple parallel lines deep to the needle (yellow arrows).

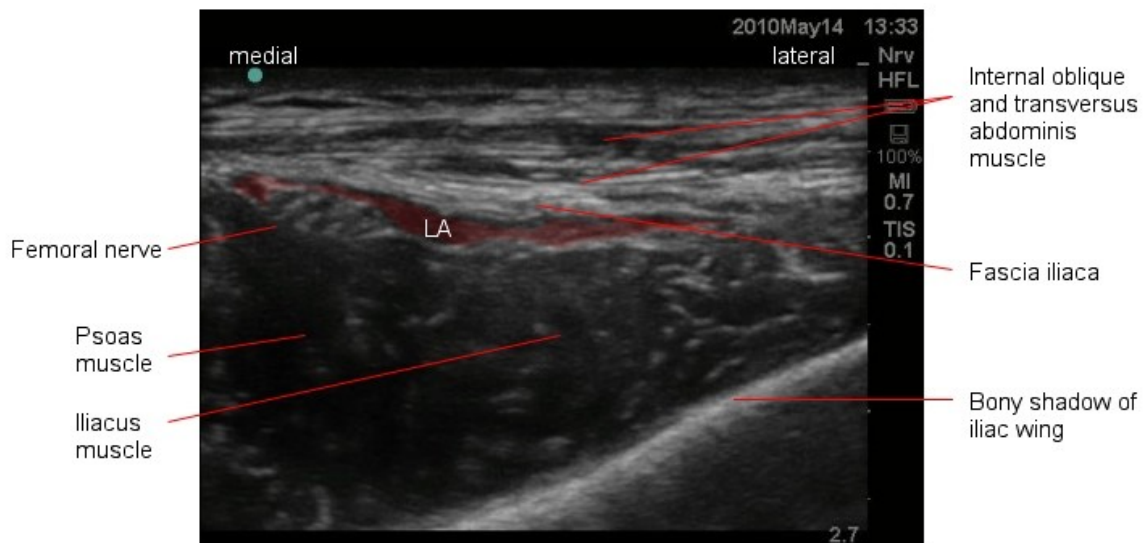


Figure 8. Local anaesthetic (LA) red cranial spread within a left fascia iliaca compartment and around the femoral nerve is observed in this US image. Taken just caudal to the anterior superior iliac spine after LA was injected caudad to the inguinal ligament.

COMPLICATIONS

COMMON TO ALL PERIPHERAL NERVE BLOCKS

- Intravascular injection
- Local anaesthetic toxicity
- Temporary or permanent nerve damage
- Infection
- Block failure
- Perioperative injury secondary to numbness or weakness

- Allergy to any of the preparations used

FICB

Overall a FICB has a very low risk profile. The location of the FICB injection means the risk of intravascular injection, local anaesthetic toxicity, and mechanical nerve damage is extremely low. Good aseptic technique will minimise the risk of infection. The injection of a large volume of local anaesthetic ensures good spread and reduces the risk of failure. The risk of local anaesthetic toxicity is highest within the first 15 minutes after injection, which makes close monitoring mandatory.

TROUBLE SHOOTING

See Table 1

Table 1: Trouble shooting

Problem	Suggested action
No distinct pops are felt during needle advancement	Withdraw the needle, check landmarks, change angle to be more perpendicular or more cranially
Hitting bone on needle advancement	Too deep, change angle directing more cranial
Blood on aspiration	Remove needle, apply pressure to needle insertion site for 2 minutes. Re-attempt, directing more laterally
Resistance to injection of local anaesthetic	Slightly withdraw the needle as it may be positioned in muscle tissue
Pain on injection	Localised slight burning sensation around the injection site is normal, slow your injection rate to ease it. Severe pain is not normal – stop injecting if this occurs
Signs of local anaesthetic toxicity (circumoral numbness, tinnitus, dizziness, seizure)	Stop injecting, call for help, give high flow oxygen, provide life support as required
No pain relief within 30 minutes	Inject further 20 ml of low concentration local anaesthetic, consider alternatives for pain relief

COMPARISON OF FICB TO A DIRECT FEMORAL NERVE BLOCK (FNB)

Because of the lower concentration of LA used for the FICB (necessary because of the higher volume required) this block does not provide a dense block and so is not suitable as a sole regional anaesthesia technique, in contrast to a direct FNB. However, FICB is a technically less demanding, safer and, if using the landmark technique, more cost-effective alternative to the direct FNB for providing analgesia.

Summary

- The Fascia Iliaca Compartment Block guided by landmarks is inexpensive, safe and easy to perform.
- Delivers effective analgesia, but not anaesthesia
- Large volumes of local anaesthetic required to achieve good spread
- Obturator nerve not reliably blocked
- Remember to always work under safe conditions

ANSWERS

1. Please answer true or false: Anatomy relevant to the Fascia Iliaca Compartment Block:
 - a. FALSE. This is the origin of the femoral and obturator nerve. The LFCN originates from L2 and L3 only.
 - b. FALSE. The femoral nerve supplies the knee extensors, whereas the knee flexors are supplied by the sciatic nerve.
 - c. TRUE. With the exception of the medial aspect, which is supplied by the saphenous nerve (branch of femoral nerve), all of the lower leg gets its sensory supply from the sciatic nerve.
 - d. FALSE. The femoral nerve is separated from the femoral vessels by a fibrous layer, part of the fascia iliaca.
 - e. TRUE. Namely femoral nerve, LFCN, and obturator nerve.

2. Please answer true or false: The following are indications for the Fascia Iliaca Compartment Block:
 - a. FALSE. Most of the ankle receives sensory supply from the sciatic nerve, which is not blocked by this technique.
 - b. TRUE. This block provides good analgesia in patients waiting for operative fixation of a fracture as well as post-operatively.
 - c. FALSE. The sensory block achieved with this technique is usually not dense enough for the use as the sole anaesthetic. Also, the posterior aspect of the thigh will not be blocked.
 - d. FALSE. Anticoagulation is a relative contra-indication for this as well as many other regional anaesthesia techniques.
 - e. FALSE. To paralyse these muscles, obturator nerve blockade is required, which is not reliably achieved with this technique.

3. Please answer true or false: With regards to techniques of FICB:
 - a. TRUE. This technique is relatively safe for these reasons.
 - b. FALSE. The landmarks are anterior superior iliac spine and pubic TUBERCLE, which lies lateral to the midline.
 - c. FALSE. With a sharp needle the sensation of a “pop” when perforating a fascial layer would not be perceived.
 - d. TRUE.
 - e. TRUE

Sign up to receive ATOTW weekly - email worldanaesthesia@mac.com

REFERENCES

- 1 Dalens et al. *Anesth Analg* 1989;69:705-13
- 2 Marhofer et al. *Anesth Analg* 1997;85:854-7
- 3 Dolan et al. *Reg Anesth Pain Med* 2008;33:526-31
- 4 Drake et al. *Gray's Anatomy for Students* 1st edition
- 5 Capdevila et al. *Anesth Analg* 1998;86:1039-44

Sources of Images:

Fig 1, 2: Gray's Anatomy of the Human Body www.bartleby.com/107/212.html
(accessed April 19th 2010)

Fig 3a, 3b, 3c, 4, 5, 6, 7, 8: C. Egeler's personal archive